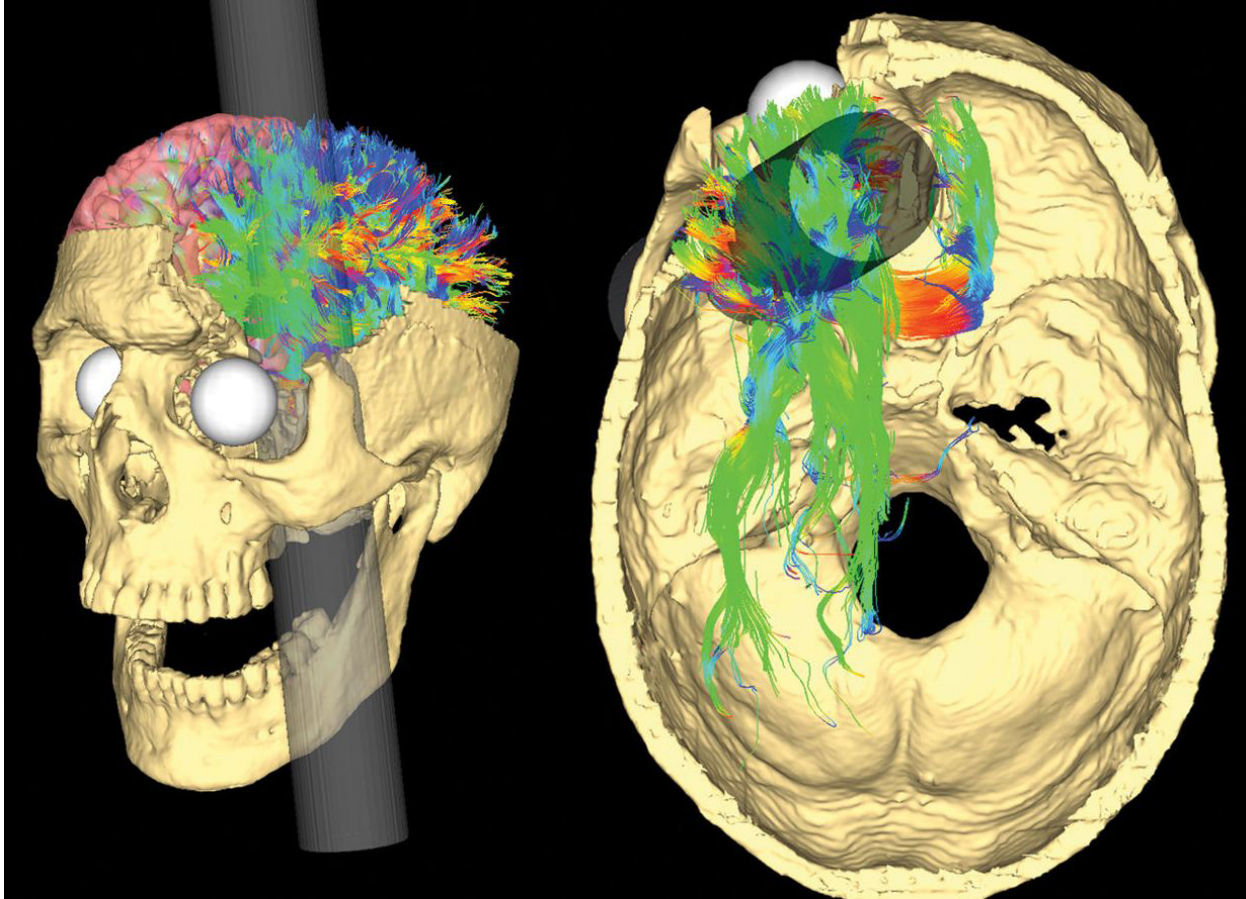

No longer Gage?

Neurology of Social Cognition



1. Hemispheric specialization

Split-brain, language lateralization, conversation

2. Prefrontal integration

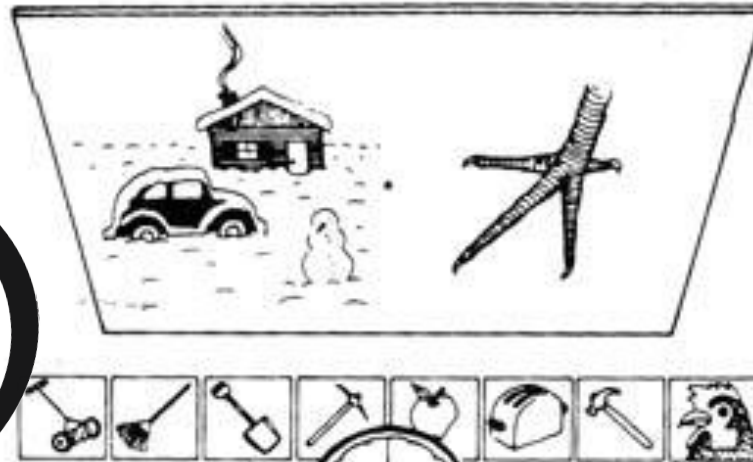
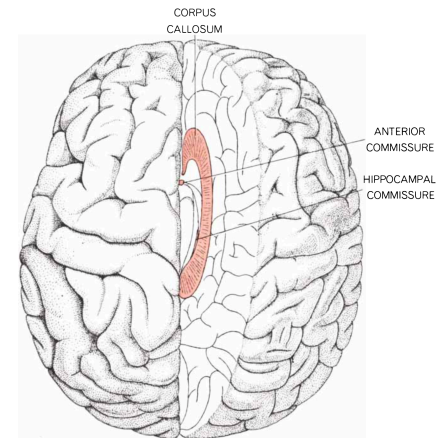
Phineas Gage, social knowledge and decisions

Split-brain patients

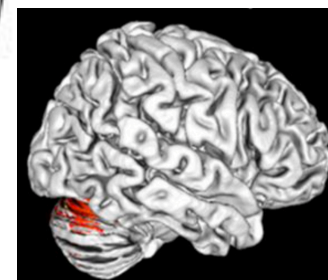
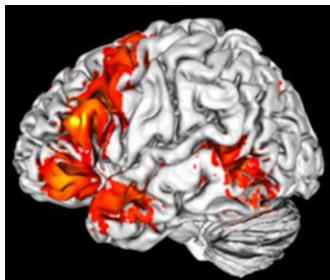
The Split Brain in Man

The human brain is actually two brains, each capable of advanced mental functions. When the cerebrum is divided surgically, it is as if the cranium contained two separate spheres of consciousness

by Michael S. Gazzaniga



“the shovel is for cleaning out the chicken coop”



The brain is actually two brains, each capable of advanced mental functions

Language lateralization

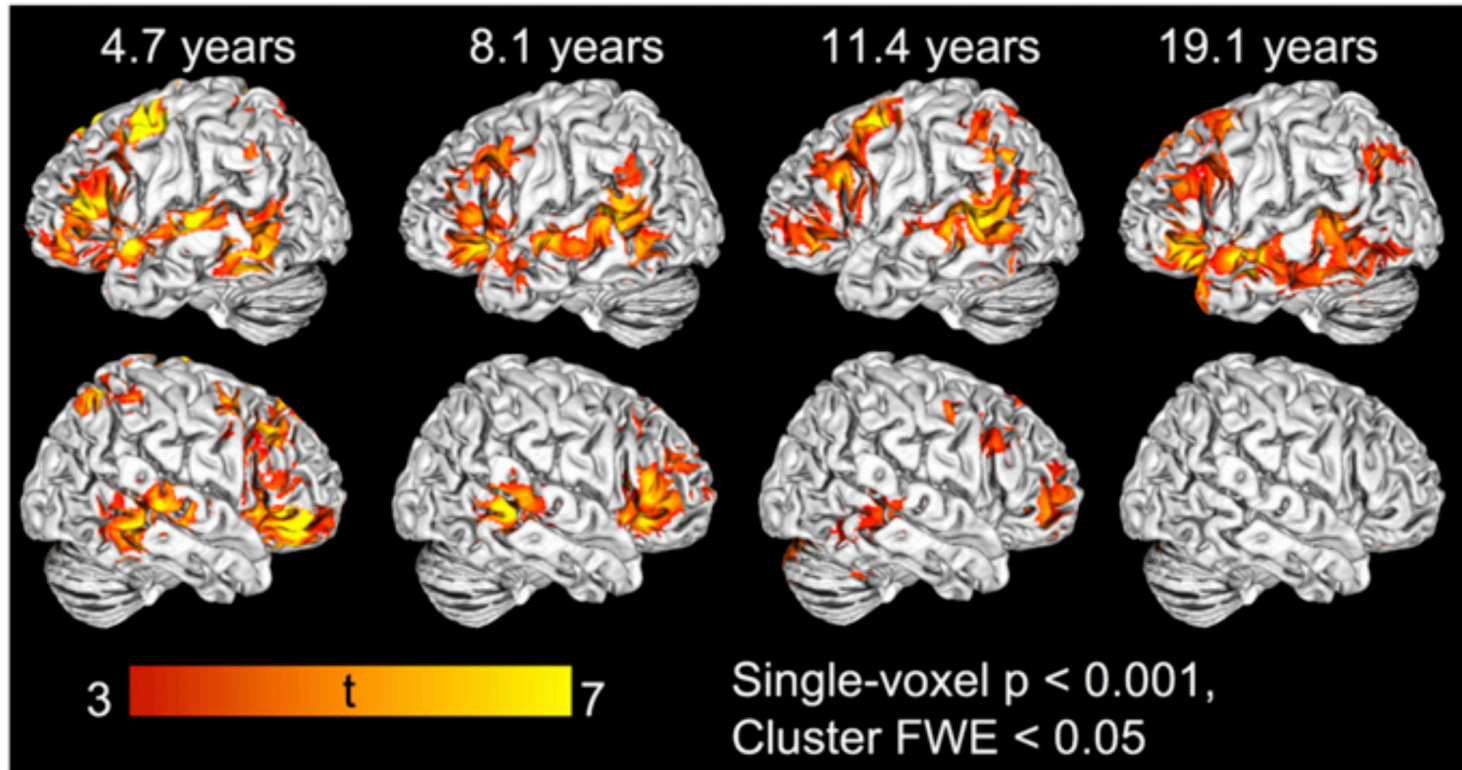


Fig. 2. Examples of individual activation maps in each of the age groups. Strong activation in right-hemisphere homologs of the left-hemisphere language areas is evident in the youngest children, declines over age, and is entirely absent in most adults.

The neural basis of language development: Changes in lateralization over age

Olumide A. Olulade^a, Anna Seydell-Greenwald^a, Catherine E. Chambers^a, Peter E. Turkeltaub^a, Alexander W. Dromerick^a, Madison M. Ber^a, William D. Gaillard^a, and Elissa L. Newport^{a,1}

Language processing is largely left-lateralized throughout life

Bilateral language acquisition

Revisiting Lenneberg's Hypotheses About Early Developmental Plasticity: Language Organization After Left-Hemisphere Perinatal Stroke

Elissa L. Newport, Barbara Landau, Anna Seydell-Greenwald, Peter E. Turkeltaub, Catherine E. Chambers, Alexander W. Dromerick, Jessica Carpenter, Madison M. Berl, & William D. Gaillard

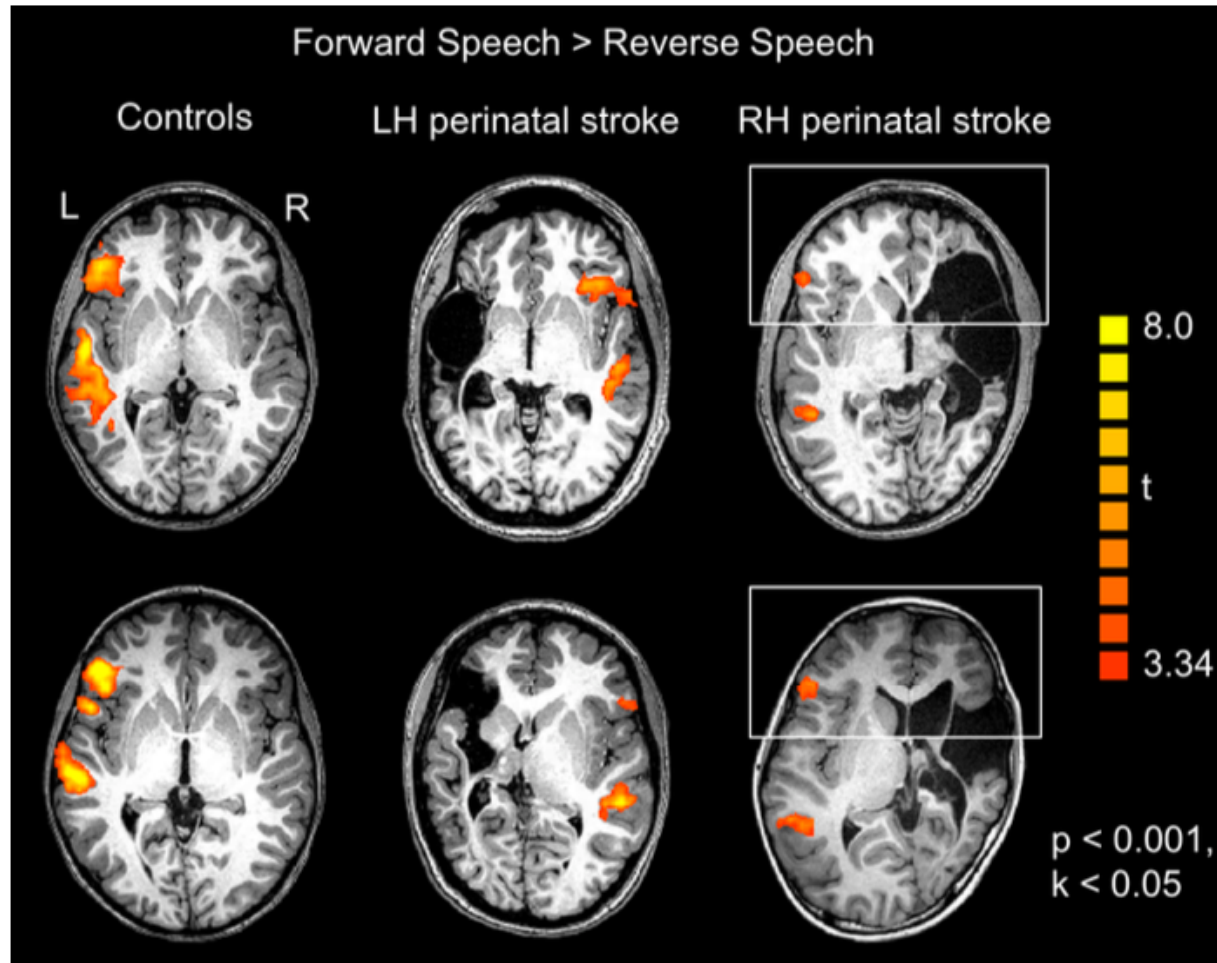


Figure 2: Example individual scans from the ADDT task, with orange/yellow showing voxels that are activated significantly more for forward than for backward speech.

However, the right hemisphere may compensate for (early) damage to the left

Right hemisphere communication deficits

- Right hemisphere patients may respond appropriately to clearly structured questions requiring specific answers, e.g., “Where do you live?”
- Yet they produce irrelevant and verbose answers to open-ended questions such as “What did you do yesterday?”
- Patients seem unable to assemble their utterances into a coherent narrative, instead wending their way through a maze of disassociated detail, without answering the question

Profiles of Communication Deficits in Patients with Right Cerebral Hemisphere Damage: Implications for Diagnosis and Treatment

Penelope S. Myers

The George Washington University Medical Center, Washington, D.C.

The right hemisphere might support conversational coherence

Right hemisphere communication deficits

For example, when asked, "Tell me about what happened to you and why you are in the hospital," one patient produced the following lengthy answer:

"Wife and I were taking - were visiting Labor Day weekend. We drove our car . . . Saturday before Labor Day weekend. Saturday morning. Let me interrupt myself - my wife and I drove our car from Washington Saturday Labor Day weekend morning. We arrive Saturday afternoon. Visit my in-laws. Saturday evening - after evening I had dinner with my in-laws. Saturday night my wife and I slept in separate rooms - my in-laws, they call it T.V. room. Always we have sleeping quarters. Saturday evening - Sun - Sunday morning when I awoke, my wife gave me breakfast. She gave me toast."

At this point the patient was reminded of the question and he continued:

"I had for breakfast, toast and egg beaters, which I like. Margarine - Fleischman's margarine . . . supposed to be low in cholesterol. My wife went in kitchen. Same - similar thing occurred to me. I was calling her. Apparently my voice sounded different. She looked. She said, 'Ohh! John has a stroke.' She was upset, so upset."

The right hemisphere might support conversational coherence

1. Hemispheric specialization

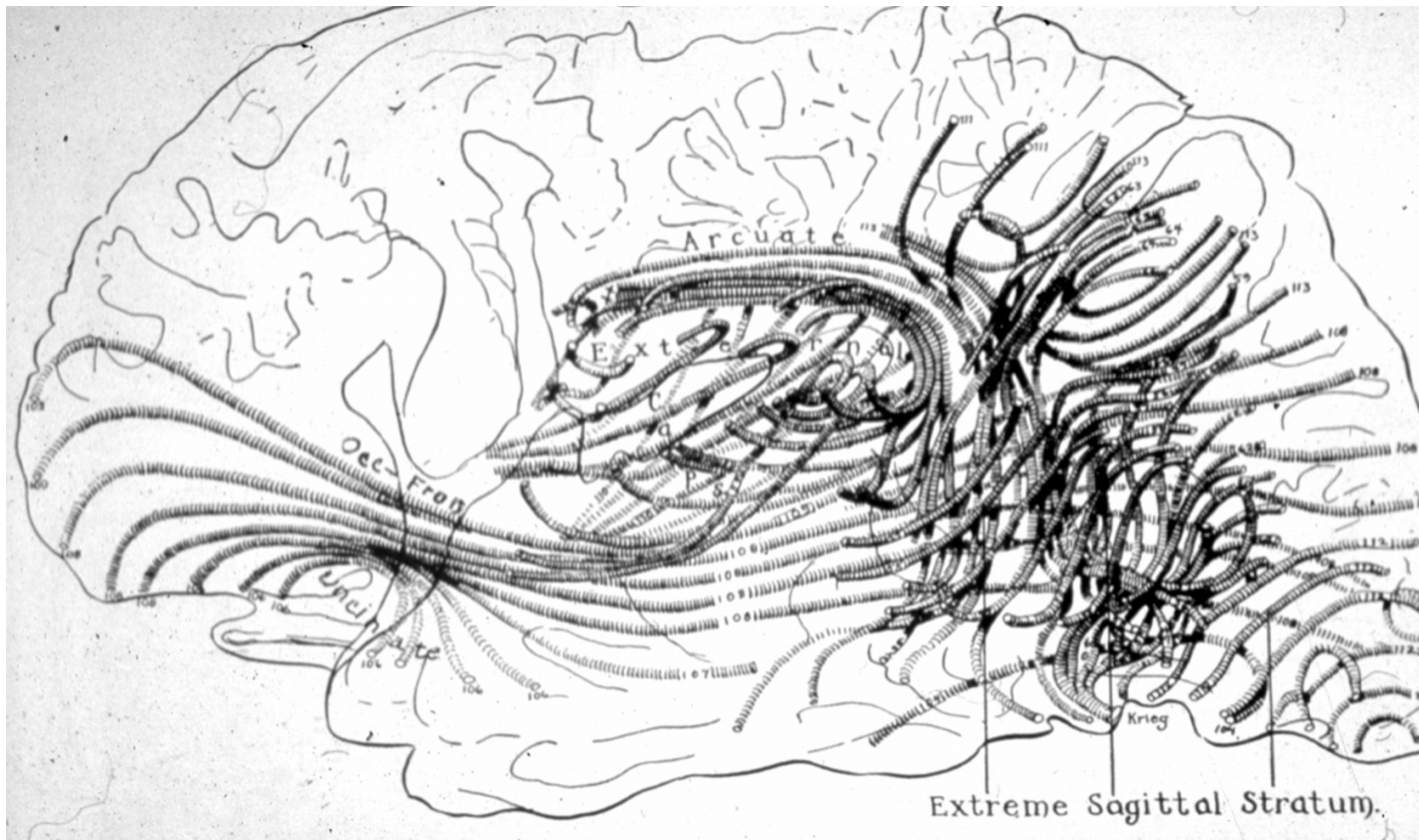
Split-brain, language lateralization, conversation

2. Prefrontal integration

Phineas Gage, social knowledge and decisions

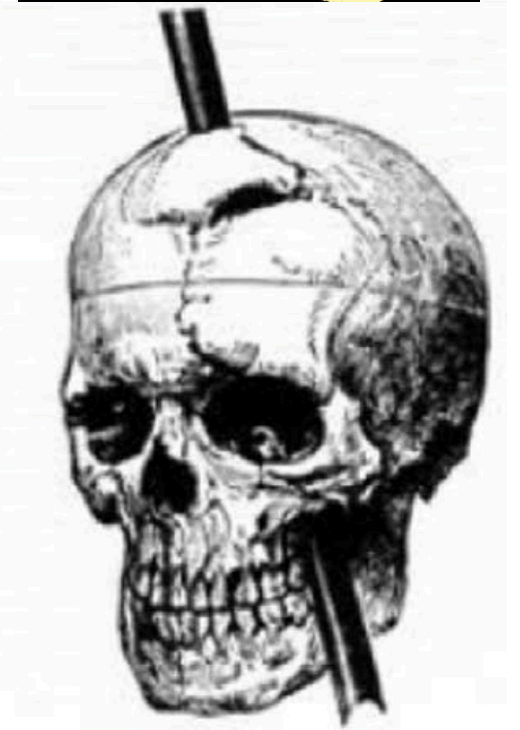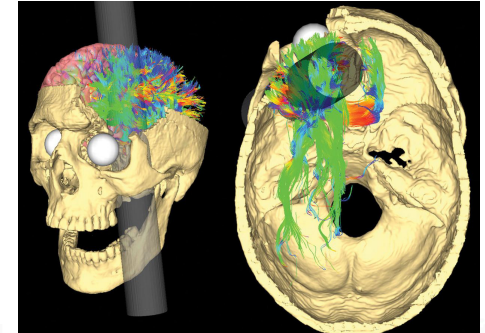



Frontotemporal connectivity



Uncinate fasciculus, a fast pathway between temporal and frontal cortex

The case of Phineas Gage (1848)



Struck by a tamping iron doing railroad construction work

Dr. Harlow about Phineas Gage

He is fitful, irreverent, indulging at times in the grossest profanity (which was not previously his custom), manifesting but little deference for his fellows, impatient of restraint or advice when it conflicts with his desires, at times pertinaciously obstinate, yet capricious and vacillating, devising many plans of future operation, which are sooner arranged than that are abandoned in turn for others appearing more feasible... In this regard his mind was radically changed, so decidedly that his friends and acquaintances said *he was “no longer Gage”*.

Gage was no longer Gage

Bilateral orbitofrontal damage



Prefrontal integration

Modern day Phineas Gage

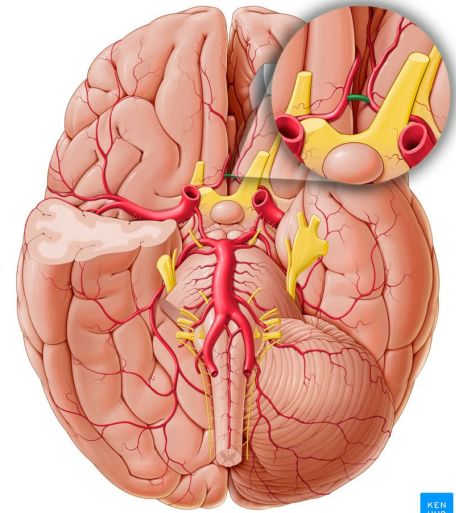
Subject: *My daughter is a modern day Phineas P. Gage*

Dear Doctor Knight:

I read with interest an article in the local paper about a recent gathering in Cavendish, VT of scientists, psychologists and neurologists to discuss the workings of the brain as related to the accident of Mr. Phineas P. Gage in 1848.

In April of 1981 it was discovered that our sixteen (16) year old daughter, D■■■■, had a giant anterior communicating aneurysm. A bifrontal craniotomy, attempted clipping of the aneurysm, exploration of the aneurysm and application of a Drake tourniquet around the left anterior cerebral was performed on 4/28/81. On 5/8/81 the closure of the Drake tourniquet was carried out under local anesthesia.

D■■■■ recovered very well and we rejoiced at the success of the surgery and of the fact that we had our beautiful, intelligent, lovable, well liked daughter intact with little "after effects" other than loss of vision in her left eye and total loss of her sense of smell. We were very happy; little did we know of what lay ahead.



© www.kenthub.com

Anterior communicating artery aneurysms can cause orbitofrontal damage

Modern day Phineas Gage

Our very delicate daughter immediately embarked on a journey of promiscuity, dare devil antics, disappearances, lying, vulgarity, shocking behavior and the likes of which we could never have imagined. Bad choices and behavioral problems have been the name of the game. It has been a horrific journey which continues even now.

A psychological profile was conducted three (3) years after surgery. The profile concluded that this was an individual who was ignorant, but with the intellect of a college graduate who engaged in shocking behavior and seemed to delight in it. The diagnosis was "borderline personality". This was explained to me as a diagnosis with symptoms similar to a bipolar disorder, but with no medications available. No connection between the brain surgery and her behavioral problems were noted.

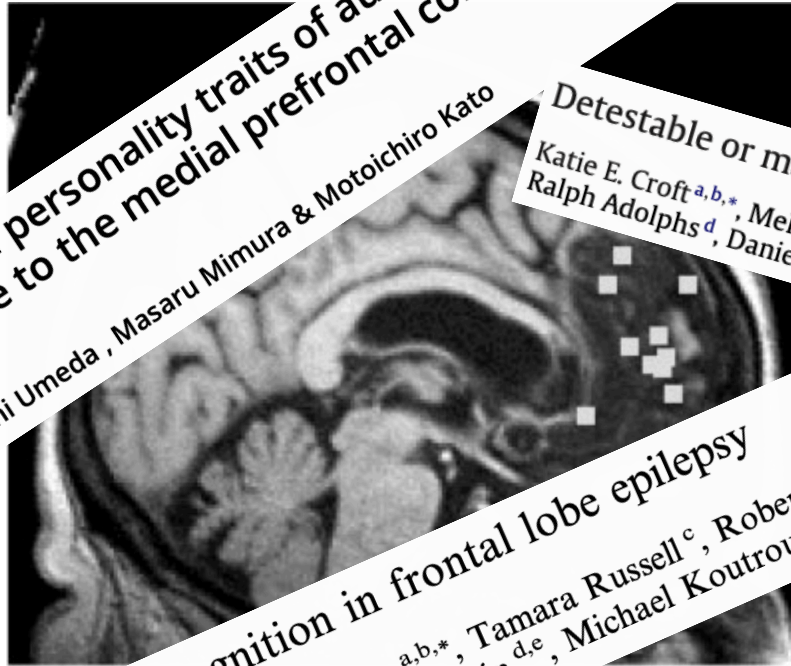
D■■■■ is thirty-three (33) years old now. The difficult life that she has chosen to live has taken a heavy toll on her and our family.

Anterior communicating artery aneurysms can cause orbitofrontal damage

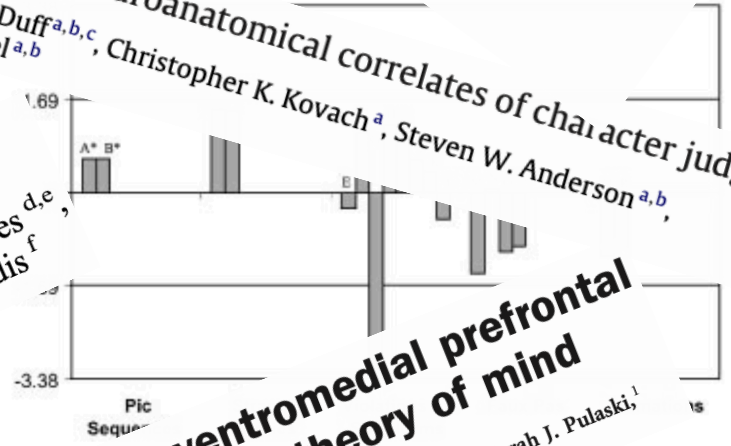
Social reasoning

Frontal Lobe Contributions to Theory of Mind
Valerie E. Stone
University of California, Davis
Simon Baron-Cohen
University of Cambridge
Robert T. Knight
University of California, Davis
The damage
Chris M. Bird,¹ Fulvia C.

Acquired personality traits of autism following damage to the medial prefrontal cortex
Satoshi Umeda, Masaru Mimura & Motoichiro Kato



Detestable or marvelous? Neuroanatomical correlates of character judgments
Katie E. Croft^{a,b,*}, Melissa C. Duff^{a,b,c},
Ralph Adolphs^d, Daniel Tranel^{a,b},
Christopher K. Kovach^a, Steven W. Anderson^{a,b}



Social cognition in frontal lobe epilepsy
Annette Farrant^a, Robin G. Morris^{a,b,*}, Tamara Russell^c, Robert Elwes^{d,e},
Nozomi Akanuma^{d,f}, Gonzalo Alarcón^{d,e}, Michael Koutroumanidis^f
different neuroimaging version of GT's lesion. Note

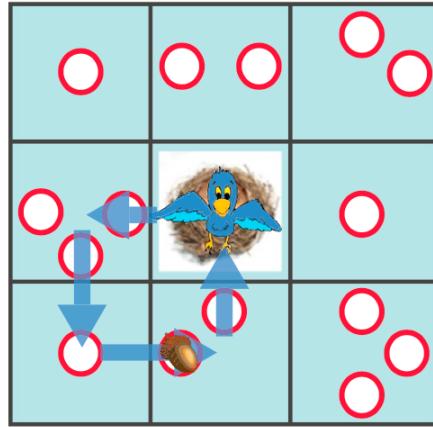
Damage to the left ventromedial prefrontal cortex impacts affective theory of mind
Anne Leopold,^{1,2} Frank Krueger,^{3,4} Olga dal Monte,^{1,5,6} Matteo Pardini,⁷ Sarah J. Pulaski,¹
Jeffrey Solomon,⁸ and Jordan Grafman

In the lab, prefrontal patients show surprising proficiency in social reasoning

Communicative decisions



Communicator
(participant)
moves the bird, visible
to the Addressee



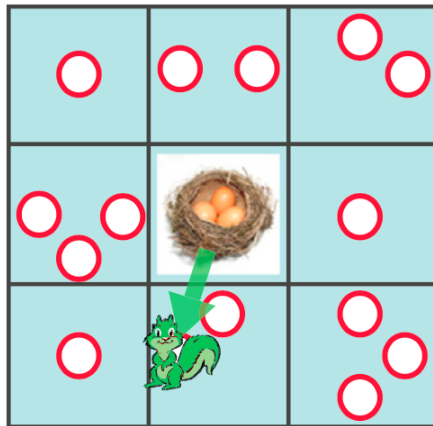
Presumed adult addressee



Presumed child addressee

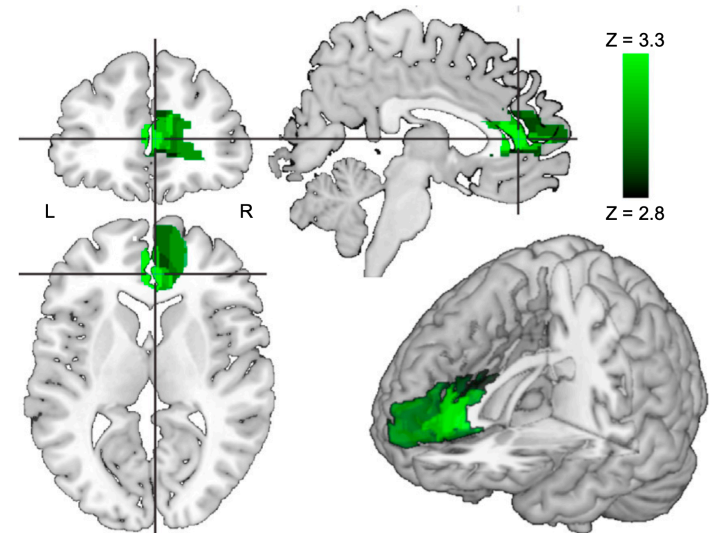


Addressee
(‘role-blind’ confederate)
collects the acorn based
on bird movements



Altered Communicative Decisions following Ventromedial Prefrontal Lesions

Arjen Stolk, Daniela D’Imperio,
Giuseppe di Pellegrino, Ivan Toni



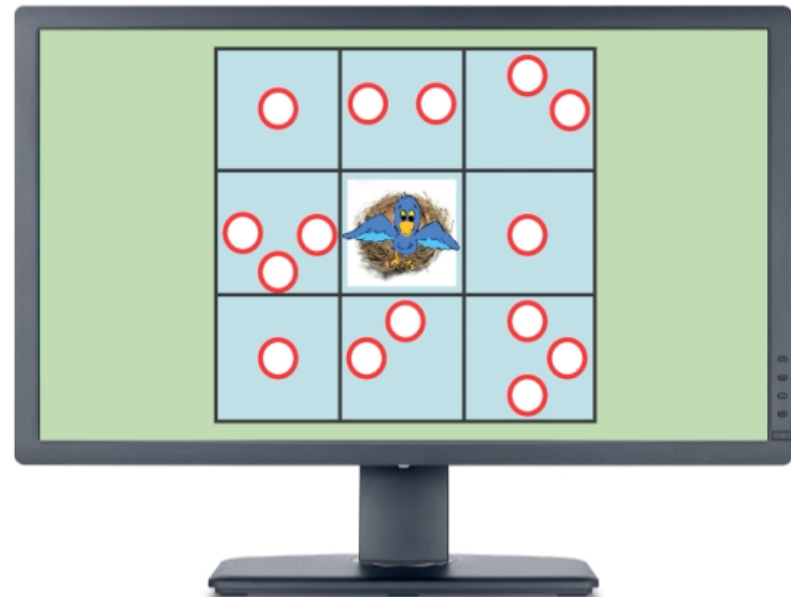
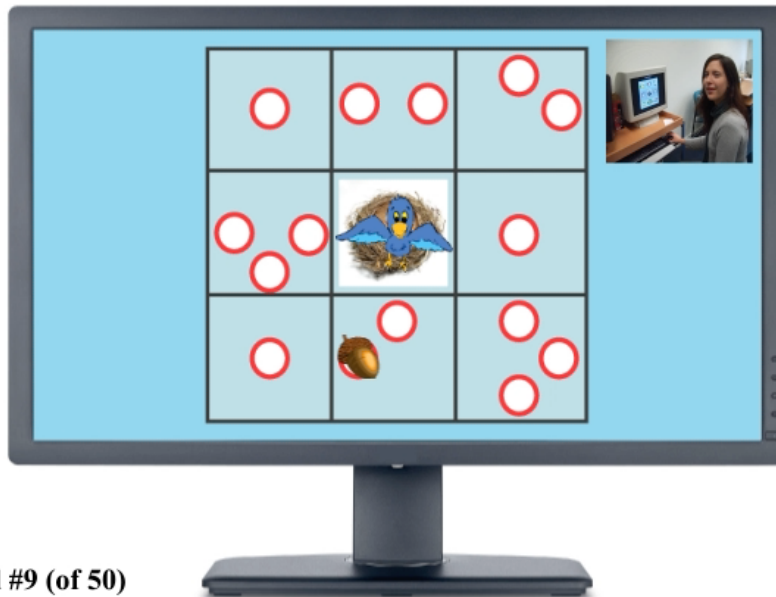
Prefrontal patients are able to select communicatively effective behaviors

Communicative decisions



PLANNING

WAIT







trial #9 (of 50)
vmPFC patient #3

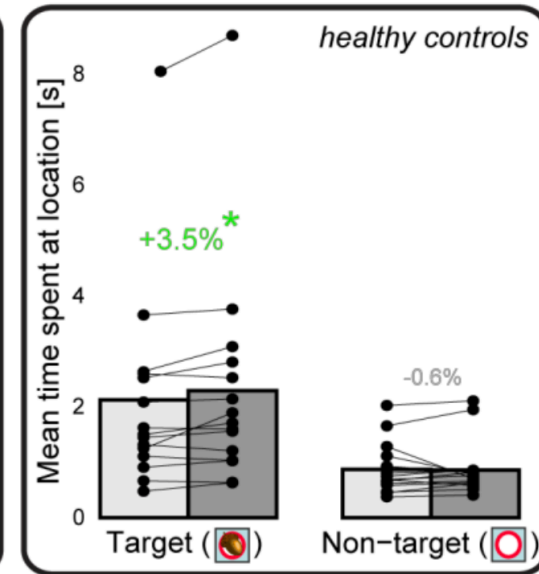
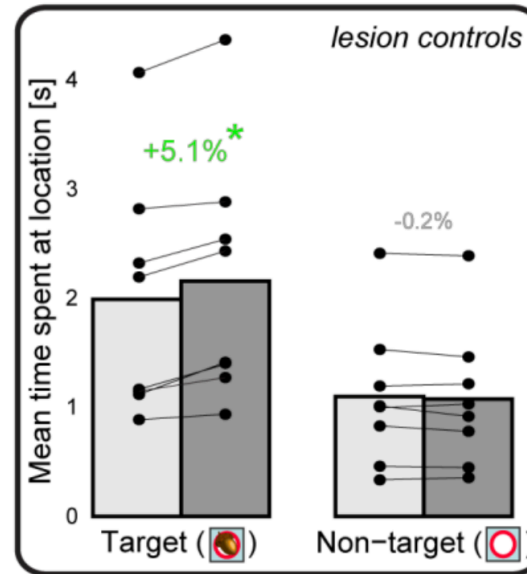
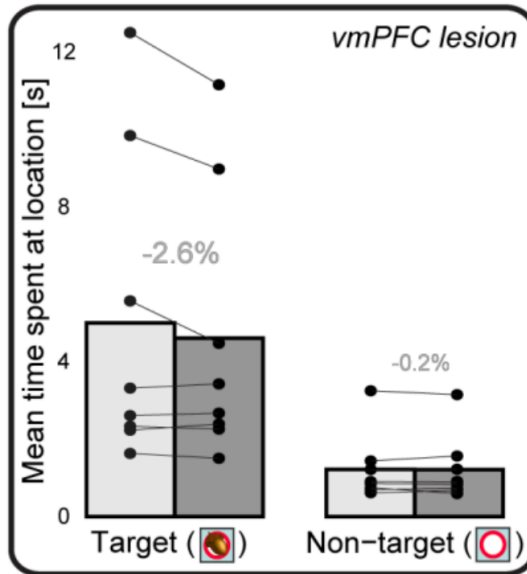
Prefrontal patients are able to select communicatively effective behaviors

Audience design

Presumed addressee

 Adult 

 Child 



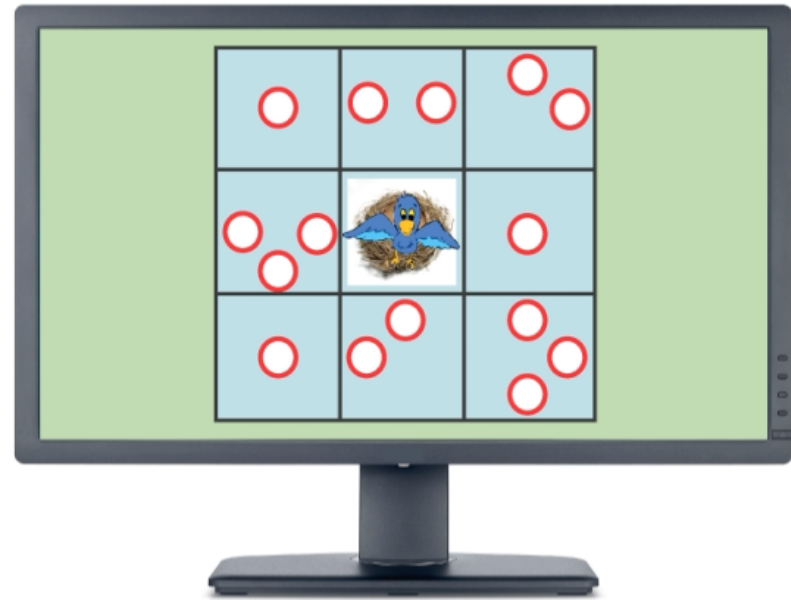
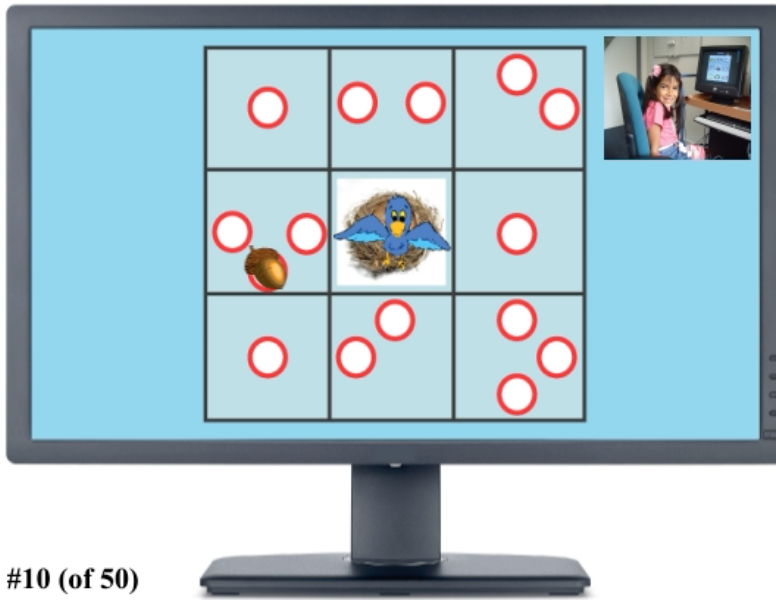
However, their decisions are not tuned to knowledge of a social partner

Audience design



PLANNING

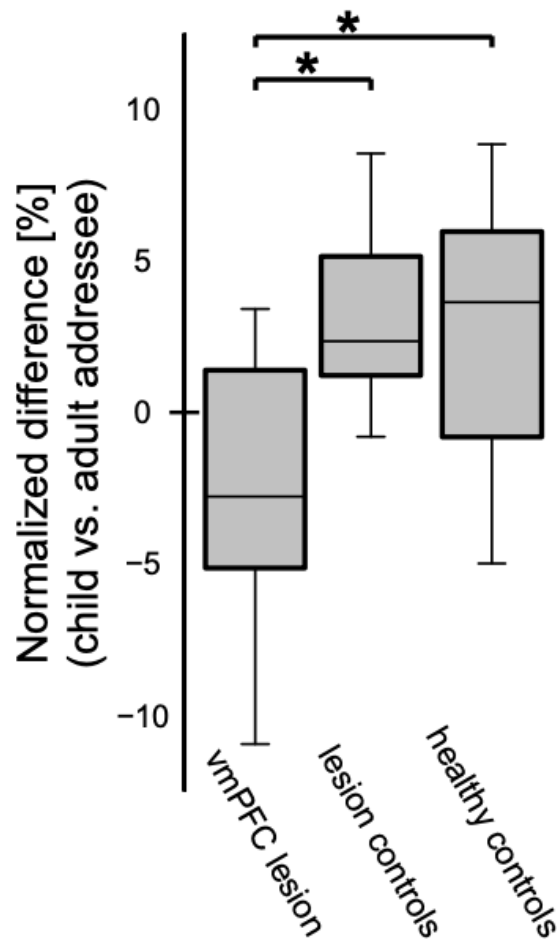
WAIT



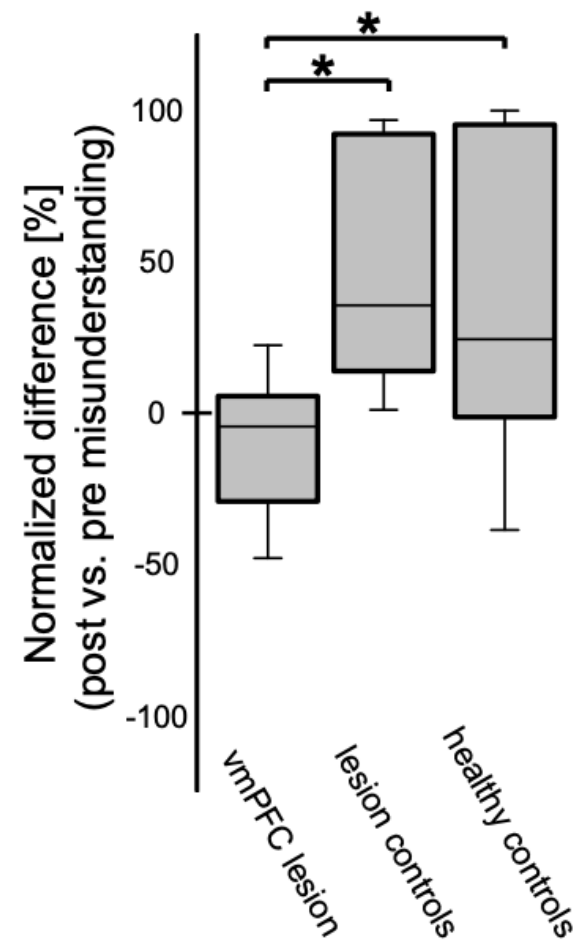
However, their decisions are not tuned to knowledge of a social partner

Repair

Communicative adjustment to addressee characteristics



Communicative adjustment following a misunderstanding

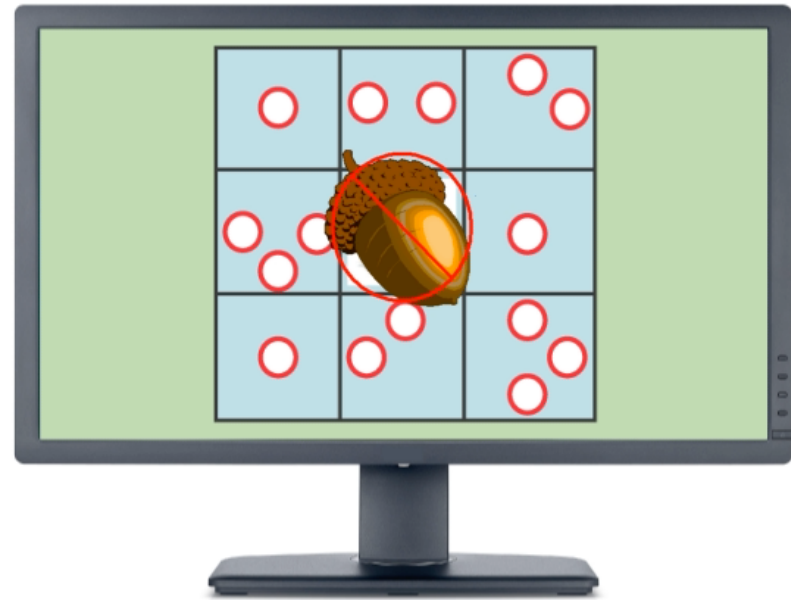
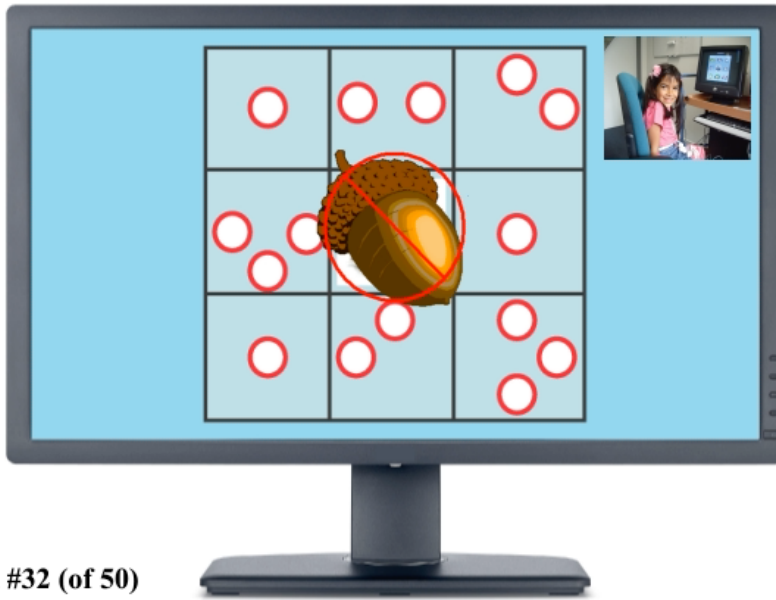


Also, prefrontal patients differentially adjust to a misunderstanding

Repair



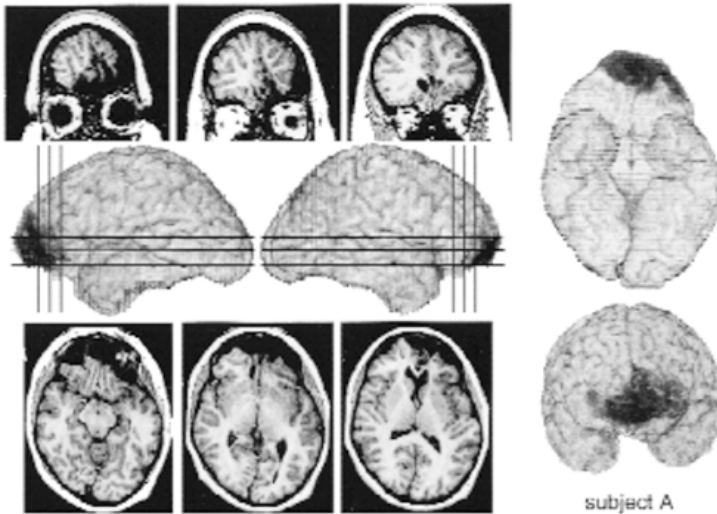
FEEDBACK



trial #32 (of 50)
vmPFC patient #7

Also, prefrontal patients differentially adjust to a misunderstanding

Acquisition of social knowledge



Impairment of social and moral behavior related to early damage in human prefrontal cortex

Steven W. Anderson, Antoine Bechara, Hanna Damasio, Daniel Tranel and Antonio R. Damasio

damage < 15 months of life

<p><u>Level 3: Postconventional</u></p> <p><u>Stage 6:</u> Personal commitment to universal moral principles.</p> <p><u>Stage 5:</u> Recognition that moral perspective may conflict with law. Consider rights and welfare of all.</p>	<p>Achieved by a minority of adults.</p> <p>One of 6 adult-onset patients at this level.</p>
<p><u>Level 2: Conventional</u></p> <p><u>Stage 4:</u> Recognition of obligations to society. The individual is viewed within the system.</p> <p><u>Stage 3:</u> Reliance on the Golden Rule. Be a good person in your own eyes and those of others.</p>	<p>Characteristic of most adults and adolescents.</p> <p>Five of 6 adult-onset patients at this level.</p>
<p><u>Level 1: Preconventional</u></p> <p><u>Stage 2:</u> Concrete reasoning that, to serve one's own needs, you must recognize other's rights.</p> <p><u>Stage 1:</u> Egocentric perspective with decisions based on avoidance of punishment.</p>	<p>Characteristic of most children under age 9.</p> <p>Both early-onset patients at this level.</p>

Unlike adult-onset patients, the rules or moral behavior are never learned

- The brain's two hemispheres have both common and unique capabilities
- The left hemisphere's role in language has been well documented. The right hemisphere's role in social interaction remains little understood
- Damage to (orbitofrontal/ventromedial) prefrontal cortex leads to profound changes in everyday social interactions, while leaving intellectual abilities intact

- Dual 4: Prefrontal Social Reasoning